

Metastatic liver mass with heart failure presentation: A case report



Asgar Mohamadi¹, Nazanin Davari², Elham Sepahvand³, Maryam Aliramezany^{2*}

¹Cardiology department, Shahid Rahimi Hospital, Lorestan University of Medical Sciences, Khorramabad, Iran

²Cardiology department, Institute of Basic and Clinical Physiology Sciences, Kerman University of Medical Sciences, Kerman, Iran

³Social Determinants of Health Research Center, Lorestan University of Medical Sciences, Khorramabad, Iran

Received: November 5, 2023

Accepted: February 10, 2024

Published online: February 24, 2024

***Corresponding author:**

Maryam Aliramezany,
Email: maliramezany@yahoo.com

Citation: Mohamadi A, Davari N, Sepahvand E, Aliramezany M. Metastatic liver mass with heart failure presentation: A case report. Journal of Emergency Practice and Trauma 2023; 9(2): x-x. doi: 10.34172/jept.2024.01

Abstract

Objective: Dyspnea is a common symptom of heart disease that can also be related to other disorders, such as liver disease. In this case report, we aim to describe a rare case of metastatic liver mass that presented with heart failure.

Case Presentation: A 50-year-old woman without a past medical history arrived at our hospital with a history of dyspnea and swelling in the lower extremities. She did not complain of pain, arthralgia, trauma, or chest pain but complained of exertional dyspnea and fatigue that had started one month before and had aggravated two days before. Her laboratory test indicated anemia. In echocardiography, we saw mild right ventricle enlargement and dysfunction, but the left heart was normal with acceptable systolic and diastolic function. In the subcostal view, the inferior vena cava (IVC) was dilated but under compression of a large liver mass. According to our literature review, this is the first case in which a metastatic liver mass had presented with heart failure.

Conclusion: In patients presenting with dyspnea, despite normal echocardiographic findings, the exact evaluation of the IVC should be considered.

Keywords: Inferior vena cava, Dyspnea, Heart failure, Liver disease

Introduction

Heart failure is a disabling syndrome characterized by a rising global prevalence influenced by underlying cardiac and cardiovascular diseases. (1). This chronic disease is the leading cause of death of about 17.9 million people worldwide and accounts for about 5% of hospital admissions in adults. Symptoms of heart failure include dyspnea, lower extremity edema, palpitations, fatigue, etc (2), and dyspnea is a common symptom that can also be related to other disorders such as acute or chronic obstructive pulmonary disease (COPD), pericardial effusion, pulmonary edema, and pulmonary embolism (3). Many factors lead to heart failure, including liver disorders (1,4). Additionally, cardiologists frequently encounter cases in which the functioning of the heart and liver mutually influence one another (5). In this case report, we describe a large metastatic liver mass that pressed the inferior vena cava (IVC) and mimicked symptoms of heart failure

Case Presentation

A 50-year-old woman without a past medical history

arrived at our hospital with a history of dyspnea and swelling in the lower extremities. She complained of exertional dyspnea that had started one month before and had worsened since two days before. She mentioned that the swelling of her legs had started one month before and had worsened in the previous two weeks. She did not complain of pain, arthralgia, trauma, or chest pain.

In the physical exam, her vital signs were heart rate (HR) = 100 beats/minute, respiratory rate (RR) = 22, and blood pressure (BP) = 100/65 mm/Hg. She was not febrile, and her oxygen saturation was 94%. We heard fine crackles from the base to mid-lung in the lung examination. In heart auscultation, S1 (first heart sound) was normal, and S2 (second heart sound) was accentuated. Furthermore, S3 (third heart sound) was heard. Her abdomen was soft without tenderness; the span of the liver was 10 cm in the right midclavicular line with mild stiffness. The lower extremities were edematous (2+) without hotness or erythema. The dorsalis pedis and posterior tibial pulses were detectable but weak. The electrocardiography (EKG) revealed sinus tachycardia with a normal axis and pulmonary P-wave. On the chest X-ray, we observed



mild right pleural effusion alongside mild cardiomegaly. In laboratory data, white blood cell (WBC)=7000; hemoglobin (Hb)=9; platelets (PLT)=140 000; uric acid (UA)=normal; albumin=3; erythrocyte sedimentation rate (ESR)=45; C-reactive protein (CRP)=3+; alanine transaminase (ALT)=236, and aspartate aminotransferase (AST)=330.

Due to the edema and right pleural effusion, a cardiology consultation was done for cardiac evaluation, especially of the right heart function.

In echocardiography, the right ventricle had mild enlargement and dysfunction. The left heart chambers had normal and acceptable systolic and diastolic function (Figure 1). Furthermore, we saw moderate tricuspid regurgitation gradient (TRG)=64 mm/Hg (Figure 2). In the costal view, the IVC was dilated but compressed by a large liver mass (Figure 3). Given the normal systolic and diastolic function of the heart and the absence of valvular disease, it appears that the dyspnea and edema in the lower extremities may be attributed to right ventricular failure. Due to the liver mass and anemia, she was suspected of gastrointestinal (GI) cancer. For better evaluation, a GI consult was done for endoscopy and colonoscopy and appropriate management.

Discussion

Heart failure is a clinical syndrome resulting from dysfunction in either the left or right ventricle. Depending on the type of involvement, it can manifest as either systolic or diastolic dysfunction (6,7). The clinical presentation of heart failure includes shortness of breath, dyspnea (84%–100% sensitivity but 17%–34% specificity), and symptoms associated with right ventricular failure, such as edema and abdominal distension (23% and 80% sensitivity and specificity, respectively) (8,9). Heart failure has a variety of symptoms, some of which are nonspecific. Thus, it can sometimes lead to misdiagnosis (9). Given that symptoms such as shortness of breath and dyspnea

have low specificity for diagnosing heart failure, other differential diagnoses such as acute or chronic COPD exacerbation, pericardial effusion, pulmonary edema, and pulmonary embolism should be considered when dealing with these clinical symptoms (10). In the absence of other cardiovascular abnormalities, liver disease may cause cardiac dysfunction and failure (2). In addition to the ordinary differential diagnoses for dyspnea, other rare differential diagnoses must be considered. For instance, in a case report, Karam and Rana described a rare case of intravascular lymphoma that presented with symptoms of dyspnea (11). Saiyed et al reported a 58-year-old man who exhibited tachypnea and a sudden onset of dyspnea. Diagnostic tests revealed bronchogenic cysts (12). In addition, Ağca et al introduced a 24-year-old man who complained of a dry cough with progressive dyspnea and acute respiratory insufficiency. After diagnostic examinations, he was finally diagnosed with pulmonary lymphangitic carcinomatosis (13).

In this case report, we present a rare case who complained of shortness of breath and lower extremity edema and was admitted with an initial diagnosis of heart failure; in further echocardiographic studies, it was found that a mass in the liver was putting pressure on the IVC, causing the patient to show clinical symptoms of heart failure. According to our literature review, this was the first case in which a metastatic liver mass caused dyspnea by putting pressure on the IVC. Thus, the learning point of our case is that in patients presenting with dyspnea, in addition to the common differential diagnoses such as cardiac and pulmonary problems, liver disease should always be considered as one of the causes of dyspnea. Another reason that can justify dyspnea and fatigue in our patients is anemia; anemia is one of the most common symptoms of colorectal cancer, and various reports indicate that anemia is more common in advanced stages of colorectal cancer (14). Our patient had advanced and metastatic colorectal cancer, and her anemia was consistent with

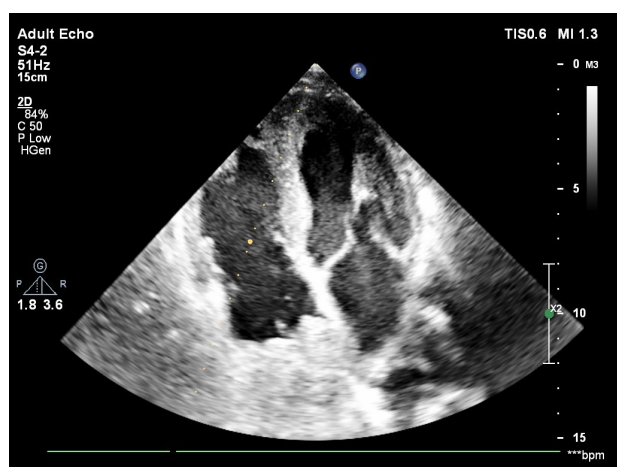


Figure 1. Normal size of both ventricles in 4-chamber view

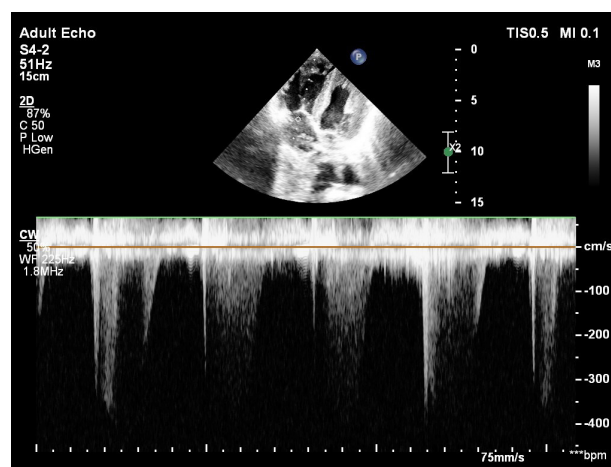


Figure 2. Moderate tricuspid regurgitation with TRG=64 mm/Hg.

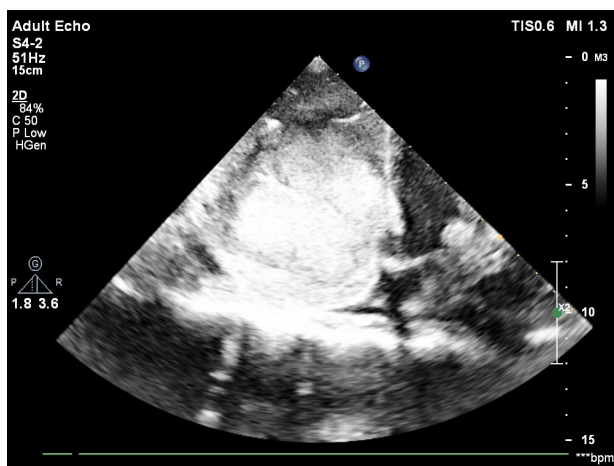


Figure 3. Large liver mass compressing the IVC in sub-costal view

the stage of cancer. Of course, apart from metastatic liver cancer, which caused dyspnea and mimicked heart failure, anemia should also be considered as one of the differential diagnoses. One of the other echocardiographic findings in our patient was IVC dilatation. Several studies have shown that IVC dilatation is one of the findings in patients with acute decompensated and chronic heart failure and is associated with increased re-admission and mortality (15,16). However, in our case, the cause of IVC dilatation was a metastatic liver mass that was putting pressure on the IVC and causing symptoms of dyspnea and heart failure. Meanwhile, other echocardiographic findings were normal, and there were no findings indicative of heart failure. Thus, in patients presenting with dyspnea, despite IVC dilatation in echocardiography and the normality of other echocardiographic findings, the pressure of liver masses on IVC should be considered in addition to the common differential diagnoses.

Conclusion

Heart failure includes a wide range of symptoms and manifestations, and timely diagnosis and proper treatment of the disease can prevent many subsequent complications. However, different pathophysiological mechanisms and etiologies can cause this disease. Therefore, in a patient presenting with shortness of breath, in addition to the common problem of heart failure, one should also think about less common etiologies, especially if the initial echocardiography results are normal.

Acknowledgments

We thank the patient's family for their consent to report the case. We also appreciate the kind staff of the hospital for their sacrifices during the COVID-19 pandemic.

Authors' Contribution

Conceptualization: Maryam Aliramezany.

Data curation: Nazanin Davari.

Formal analysis: Maryam Aliramezany, Asghar Mohamadi.

Funding acquisition: Maryam Aliramezany.

Investigation: Nazanin Davari.

Project administration: Maryam Aliramezany.

Resources: Nazanin Davari.

Software: Asghar Mohamadi.

Supervision: Maryam Aliramezany.

Validation: Elham Sepahvand.

Visualization: Maryam Aliramezany.

Writing—original draft: Asghar Mohamadi, Elham Sepahvand.

Writing—review & editing: Maryam Aliramezany, Nazanin Davari.

Competing Interests

None.

Data Availability Statement

This does not apply to case reports; however, anonymous medical records are available upon request from the corresponding author.

Ethical Approval

As there was no experimental intervention in this case, the need for ethical approval was waived. Additionally, the patient received medical care, for which she declared her informed written consent to the hospital. We obtained the patient's family's (her legal guardians') written consent to report her case; we assured them this would be done anonymously.

Funding

None.

References

- Correale M, Tarantino N, Petrucci R, Tricarico L, Laonigro I, Di Biase M, et al. Liver disease and heart failure: back and forth. *Eur J Intern Med.* 2018;48:25-34. doi: [10.1016/j.ejim.2017.10.016](https://doi.org/10.1016/j.ejim.2017.10.016).
- Benincasa G, Cuomo O, Vasco M, Vennarecci G, Canonico R, Della Mura N, et al. Epigenetic-sensitive challenges of cardiohepatic interactions: clinical and therapeutic implications in heart failure patients. *Eur J Gastroenterol Hepatol.* 2021;33(10):1247-53. doi: [10.1097/meg.0000000000001867](https://doi.org/10.1097/meg.0000000000001867).
- Obokata M, Reddy YNV, Borlaug BA. The role of echocardiography in heart failure with preserved ejection fraction: what do we want from imaging? *Heart Fail Clin.* 2019;15(2):241-56. doi: [10.1016/j.hfc.2018.12.004](https://doi.org/10.1016/j.hfc.2018.12.004).
- Xanthopoulos A, Starling RC, Kitai T, Triposkiadis F. Heart failure and liver disease: cardiohepatic interactions. *JACC Heart Fail.* 2019;7(2):87-97. doi: [10.1016/j.jchf.2018.10.007](https://doi.org/10.1016/j.jchf.2018.10.007).
- Nagueh SF, Smiseth OA, Appleton CP, Byrd BF 3rd, Dokainish H, Edvardsen T, et al. Recommendations for the evaluation of left ventricular diastolic function by echocardiography: an update from the American Society of Echocardiography and the European Association of Cardiovascular Imaging. *Eur Heart J Cardiovasc Imaging.* 2016;17(12):1321-60. doi: [10.1093/ehjci/jew082](https://doi.org/10.1093/ehjci/jew082).
- Inamdar AA, Inamdar AC. Heart failure: diagnosis, management and utilization. *J Clin Med.* 2016;5(7):62. doi: [10.3390/jcm5070062](https://doi.org/10.3390/jcm5070062).
- Moazenzadeh M, Jafari F, Farrokhnia M, Aliramezany M. First reported case of unrepaired tetralogy of Fallot complicated with coronavirus disease-19 (COVID-19). *Cardiol Young.* 2020;30(9):1339-42. doi: [10.1017/s1047951120001821](https://doi.org/10.1017/s1047951120001821).
- Yancy CW, Jessup M, Bozkurt B, Butler J, Casey DE Jr, Drazner MH, et al. 2013 ACCF/AHA guideline for the management of heart failure: a report of the American College of Cardiology Foundation/American Heart Association Task Force on Practice Guidelines. *J Am Coll Cardiol.* 2013;62(16):e147-239. doi: [10.1016/j.jacc.2013.05.019](https://doi.org/10.1016/j.jacc.2013.05.019).
- Watson RD, Gibbs CR, Lip GY. ABC of heart failure. *Clinical*

- features and complications. *BMJ*. 2000;320(7229):236-9. doi: [10.1136/bmj.320.7229.236](https://doi.org/10.1136/bmj.320.7229.236).
10. Rawat D, Sharma S. Case study: 60-year-old female presenting with shortness of breath. In: *StatPearls* [Internet]. Treasure Island, FL: StatPearls Publishing; 2021.
 11. Karam I, Rana M. CLO22-057: a rare case of intravascular lymphoma presenting with dyspnea and bilateral lung infiltrates. *J Natl Compr Canc Netw*. 2022;20(3.5):CLO22-057. doi: [10.6004/jnccn.2021.7322](https://doi.org/10.6004/jnccn.2021.7322).
 12. Saiyed H, Bachan M, Siegel R, Khan Z. Bronchogenic cyst as the cause of respiratory compromise in an adult. *Am J Respir Crit Care Med*. 2017;195:A5487.
 13. Ağca M, Akyıl FT, Hörmet M, Akman O, Akman C, Şen A, et al. A rare case of progressive dyspnea and bilateral lung infiltration in a young male. *Turk Thorac J*. 2017;18(3):96-9. doi: [10.5152/TurkThoracJ.2017.16052](https://doi.org/10.5152/TurkThoracJ.2017.16052).
 14. Väyrynen JP, Tuomisto A, Väyrynen SA, Klintrup K, Karhu T, Mäkelä J, et al. Preoperative anemia in colorectal cancer: relationships with tumor characteristics, systemic inflammation, and survival. *Sci Rep*. 2018;8(1):1126. doi: [10.1038/s41598-018-19572-y](https://doi.org/10.1038/s41598-018-19572-y).
 15. Jobs A, Brünjes K, Katalinic A, Babaev V, Desch S, Reppel M, et al. Inferior vena cava diameter in acute decompensated heart failure as predictor of all-cause mortality. *Heart Vessels*. 2017;32(7):856-64. doi: [10.1007/s00380-017-0944-0](https://doi.org/10.1007/s00380-017-0944-0).
 16. Moosazadeh M, Nekoei-Moghadam M, Aliram-Zany M, Amiresmaili M. Identification of mutation of glucose-6-phosphate dehydrogenase (G6PD) in Iran: meta-analysis study. *Iran J Public Health*. 2013;42(9):1007-15.